

A giant pulmonary artery aneurysm associated with congenital keratoglobus

Doğumsal keratoglobus ile ilişkili dev pulmoner arter anevrizması

İhsan Alur,¹ Tefik Güneş,¹ Gökhan Pekel,² Bilgin Emrecan¹

Departments of ¹Cardiovascular Surgery, ²Ophthalmology, Medical Faculty of Pamukkale University, Denizli, Turkey

ABSTRACT

Pulmonary artery aneurysms are rare pathologies which may present with Marfan syndrome, Ehler-Danlos syndrome, or collagen tissue diseases. These aneurysms may originate from non-congenital causes, such as pulmonary arterial hypertension, tuberculosis, syphilis, candida, mucormycosis, Behçet's disease, giant-cell arteritis, or post-trauma vasculitis. The presence of pulmonary artery aneurysm and those of the ascending aorta and aortic root along with a single coronary ostium abnormality accompanied by congenital keratoglobus is a very rare condition. Herein, we present a 33-year-old male with congenital keratoglobus who underwent surgery for a pulmonary artery aneurysm associated with aneurysms of the aorta and aortic root, as well as advanced aortic insufficiency.

Keywords: Aneurysm; aortic root aneurysm; congenital keratoglobus; pulmonary artery.

A pulmonary artery aneurysm (PAA) is defined as a pulmonary artery diameter >4 cm.^[1] It is a rare cardiovascular disease with an incidence of 0.007% based on an autopsy study.^[1] The most common symptoms in patients with a PAA are shortness of breath, fatigue, palpitations, chest pain, cough, hemoptysis, and hoarseness.^[1] Some congenital and acquired risk factors for PAAs have also been reported. Congenital causes include collagen tissue diseases such as Marfan syndrome, Ehler-Danlos syndrome, Loeys-Dietz syndrome, arterial tortuosity syndrome, and pulmonary valve stenosis, or intra-cardiac congenital heart diseases with a left-to-right shunt such as a ventricular septal defect, an atrial septal defect,

ÖZ

Pulmoner arter anevrizmaları Marfan sendromu, Ehler-Danlos sendromu veya kollajen doku hastalıkları ile birlikte görülebilen, nadir patolojilerdir. Bu anevrizmalar pulmoner arteriyel hipertansiyon, tüberküloz, sifiliz, kandida, mukormikozis gibi enfeksiyonlar, Behçet hastalığı, dev hücreli arterit gibi vaskülitler veya travma sonrası vaskülit gibi doğumsal olmayan nedenlerle de ortaya çıkabilir. Doğumsal keratoglobusun eşlik ettiği tek koroner ostiyum anomalisi ile birlikte pulmoner arter anevrizması ve çıkan aort ve aort kökü anevrizmaları oldukça nadir bir durumdur. Bu yazıda, ileri aort yetersizliğinin yanı sıra, aort ve aort kökü anevrizmaları ile ilişkili pulmoner arter anevrizması nedeniyle cerrahi uygulanan, doğumsal keratoglobuslu 33 yaşında bir erkek olgu sunuldu.

Anahtar sözcükler: Anevrizma; aort kökü anevrizması; doğumsal keratoglobus; pulmoner arter.

and patent ductus arteriosus.^[1-4] On the other hand, acquired causes include chronic obstructive pulmonary disease, valvular heart diseases resulting in pulmonary hypertension (PHT), vasculitis such as Behçet's disease or giant-cell arteritis, infections such as tuberculosis, syphilis, septic embolism, or arteriovenous fistula, extravascular or intravascular post-trauma, and degenerative diseases including atherosclerosis and cystic medial degeneration.^[1-4] Beyond this, several PAA cases without any underlying cause have been also reported in the literature.^[1-3]

Herein, we present a male patient with congenital keratoglobus who underwent surgery due to a PAA



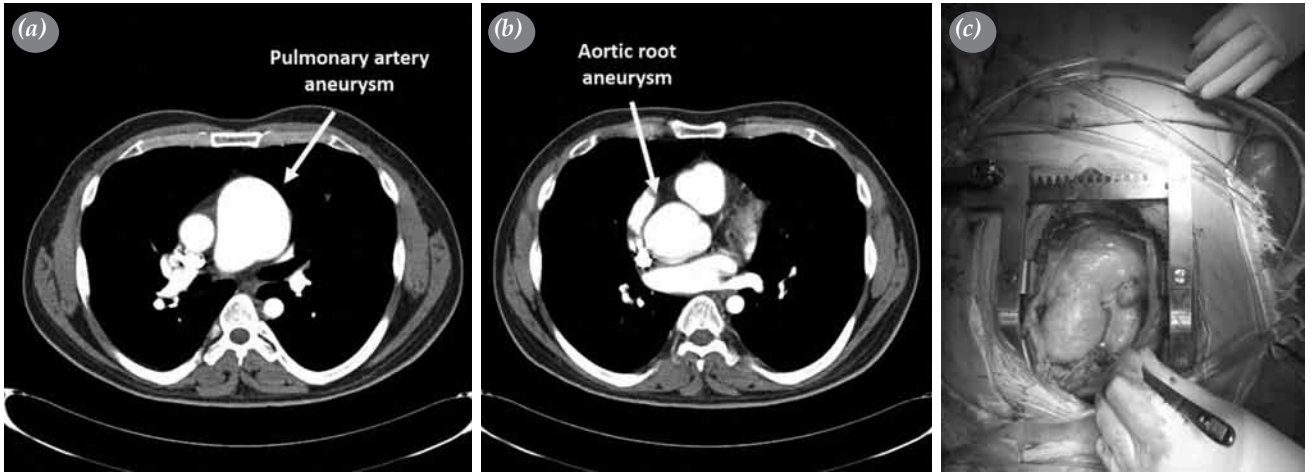


Figure 1. (a) A computed tomography angiography image of a pulmonary artery aneurysm, (b) aortic root aneurysm, (c) intraoperative view.

associated with an aneurysm of the aorta and the aortic root, as well as advanced aortic insufficiency.

CASE REPORT

A 33-year-old male presented with complaints of chest and back pain and shortness of breath. On auscultation, a cardiac murmur was heard and transthoracic echocardiography revealed fourth-degree aortic valvular insufficiency. The aortic valve was of tricuspid structure without a pathological gradient, and systolic PA pressure was normal. It was reported as the first-degree mitral and first-degree tricuspid insufficiency with an ejection fraction of 62%. The truncus pulmonalis was dilated and 62 mm at its widest point. An electrocardiogram showed sinus rhythm, and the patient was in the New York Heart Association (NYHA) functional class I. A contrast-enhanced thoracic computed tomography scan of the aortic root revealed a size of 55 mm; the supra-avalvular aortic diameter was 28 mm, and the pulmonary conus was dilated and 61 mm at its widest point (Figures 1a-c). Keratoglobus was detected by ocular examination, as

the patient reported having a congenital ocular corneal disorder (Figures 2a, b). His best corrected visual acuity was 20/200 in both eyes. However, we did not detect a dislocated lens or retinal abnormality. Intraocular pressure was within normal limits (11 mmHg in the OD and 12 mmHg in the OS).

Cardiopulmonary bypass, median sternotomy, and aorticaval cannulation were performed under general anesthesia. The aorta was cross-clamped, the aneurysmal ascending aortic segment was resected, and cardiac arrest was produced through selective antegrade cardioplegia. Isothermic hypercalcemic blood cardioplegia was used as the cardioplegic solution. Cardioplegia was provided intermittently through the antegrade route and continuously through the retrograde routes during surgery. The aortic leaflets were excised and the right and left ostia originated from a single ostium. An anastomosis was performed using an 8 mm Dacron graft, and another anastomosis was, then, performed to the aortic root with a No. 23 mechanic (Carbomedics; Sorin Group, Milan, Italy) aortic valve and a No. 26 composite graft. Following

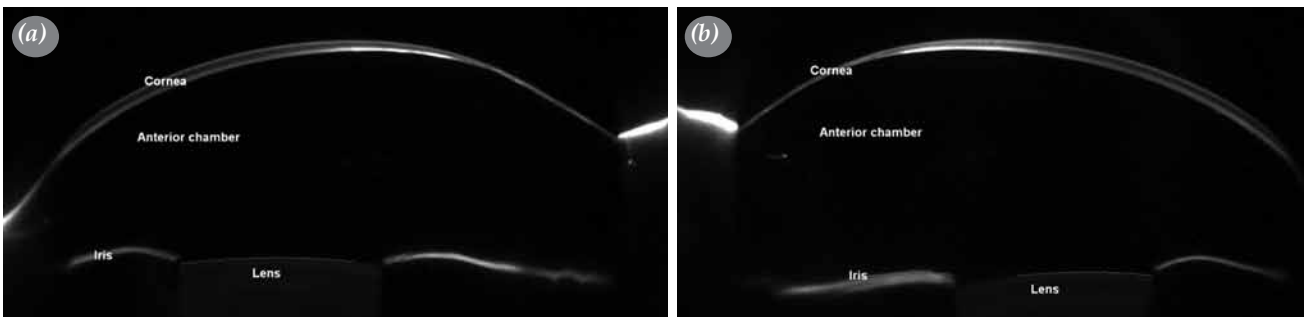


Figure 2. Anterior segment Scheimpflug images of the (a) right and (b) left eyes.

this anastomosis, the prepared coronary button was appropriately anastomosed to the composite graft. Then, the aneurismal segment of the pulmonary artery extending from the infundibulum towards the bifurcation was resected and anastomosed to the first parts of the right and left pulmonary arteries with a 26 mm Dacron graft. An air-removing procedure was applied to this graft and the cross-clamp was removed. Then, a pulmonary graft proximal anastomosis was performed on the beating heart. The resected aorta and pulmonary artery segment were sent for pathological examination, which revealed that the media layer was detached with fibrin accumulation in the detached areas. The patient was discharged from the hospital without any postoperative complications on the postoperative seventh day.

DISCUSSION

A structural collagen tissue disorder or infection, thinning/weakening of the pulmonary artery wall due to chronic inflammation, wall tension created by degeneration, and chronic pressure/volume overload have been suggested to create the basic pathophysiological mechanism for the development of a PAA.^[1-3] Pulmonary artery dissection or rupture, which is a fatal complication, develops in approximately one-third of patients with a PAA.^[1-3] Other severe complications are right cardiac failure due to pulmonary valve regurgitation, coronary ischemia secondary to left main coronary artery pressure, airway obstruction due to tracheal bronchial pressure, hoarseness due to recurring laryngeal nerve pressure, and formation of a thrombus inside the aneurysm, leading to thromboembolism.^[1,5-8] Our case had also chest pain and shortness of breath; however, no serious complications related to the PAA developed.

On the other hand, coronary artery abnormalities (CAAs) are rare with an incidence of 0.6 to 1.3% in angiographic series.^[9,10] Life-threatening arrhythmias, syncope, myocardial infarction, and sudden death develop in about 20% of patients with this anomaly.^[9,10] Also, CAAs are the second most common cause of sudden cardiac death in young athletes.^[9] Furthermore, a single coronary ostium anomaly is a rare entity with an incidence of 0.35% in a study.^[9] In our case, the right and left main coronary arteries exited from the left coronary ostium. His complaints of chest and back pain suggested coronary ischemia due to the PAA pressure.

Medical treatment is recommended to improve clinical symptoms and findings of PAAs. If pulmonary arterial hypertension (PAH) accompanies a PAA,

calcium channel blockers, anticoagulant treatment, and sildenafil citrate can be administered.^[2] Boerrigter et al.^[5,10] reported that, although pulmonary vascular resistance improved to near normal in patients treated for 20 months with calcium channel blockers, the PAA diameter did not decrease and the PAA enlarged progressively independent of hemodynamic variables, such as PA pressure or cardiac output.

Nonetheless, there is no clear consensus on the surgical treatment for a PAA. Some authors advocate surgical repair and recommend surgical intervention when the PA is dissected or the PA diameter increases progressively.^[2,5] Enlargement of an aortic aneurysm may not be as progressive as it is in the aorta of a patient with PHT or if no intracardiac left-to-right shunt is present. However, surgical treatment is required in cases of right ventricular dysfunction, severe valvular insufficiency, and symptomatic patients with chest pain, shortness of breath, coughing, and hemoptysis, as an aneurysm of >6 cm has an increased risk of rupture.^[2,8] Possible choices for surgical treatment of a PAA include interposition with a Dacron or homograft, repair with a pericardial patch, aneurysmorrhaphy, and arterioplasty.^[2] In our case, we performed surgical repair, as our case was symptomatic and had severe aortic valve insufficiency and a PAA together along with an aneurysm of the ascending aorta and the aortic root.

In conclusion, concurrent aneurysms of the pulmonary artery, ascending aorta, and aortic root along with a single coronary ostium anomaly and congenital keratoglobus are extremely rare. To the best of our knowledge, this is the first case of a combination of all of these manifestations. We recommend surgery with successful outcomes in these patients.

Declaration of conflicting interests

The authors declared no conflicts of interest with respect to the authorship and/or publication of this article.

Funding

The authors received no financial support for the research and/or authorship of this article.

REFERENCES

1. Sheikhzadeh S, De Backer J, Gorgan NR, Rybczynski M, Hillebrand M, Schüler H, et al. The main pulmonary artery in adults: a controlled multicenter study with assessment of echocardiographic reference values, and the frequency of dilatation and aneurysm in Marfan syndrome. *Orphanet J Rare Dis* 2014;9:203.
2. Nair KK, Cobanoglu AM. Idiopathic main pulmonary artery aneurysm. *Ann Thorac Surg* 2001;71:1688-90.
3. Tuncer A, Tuncer EY, Tas SG, Erdem H, Polat A. Repair of pulmonary artery aneurysms. *J Card Surg* 2011;26:501-5.

4. Ozer PA, Yalniz-Akkaya Z. Congenital keratoglobus with multiple cardiac anomalies: a case presentation and literature review. *Semin Ophthalmol* 2015;30:305-12.
5. Araújo I, Escribano P, Lopez-Gude MJ, Lopez-Guarch CJ, Sanchez MA, Ruiz-Cano MJ, et al. Giant pulmonary artery aneurysm in a patient with vasoreactive pulmonary hypertension: a case report. *BMC Cardiovasc Disord* 2011;11:64.
6. Shankarappa RK, Moorthy N, Chandrasekaran D, Nanjappa MC. Giant pulmonary artery aneurysm secondary to primary pulmonary hypertension. *Tex Heart Inst J* 2010;37:244-5.
7. Albadri K, Jensen JM, Christiansen EH, Mellekjær S, Nielsen-Kudsk JE. Left main coronary artery compression in pulmonary arterial hypertension. *Pulm Circ* 2015;5:734-6.
8. Başaran M, Çine N, Kafalı E, Yayla TE, Güzelmeriç F, Arslan A, et al. Pulmonary artery aneurysm leading to coronary ischemia. *Türk Göğüs Kalp Dama* 2014;22:149-51.
9. Graidis C, Dimitriadis D, Karasavvidis V, Dimitriadis G, Argyropoulou E, Economou F, et al. Prevalence and characteristics of coronary artery anomalies in an adult population undergoing multidetector-row computed tomography for the evaluation of coronary artery disease. *BMC Cardiovasc Disord* 2015;15:112.
10. Boerrigter B, Mauritz GJ, Marcus JT, Helderma F, Postmus PE, Westerhof N, et al. Progressive dilatation of the main pulmonary artery is a characteristic of pulmonary arterial hypertension and is not related to changes in pressure. *Chest* 2010;138:1395-401.